

Lipoblastic meningioma: Case Report and Literature Review

Zahra Mardanshahi^{1*}, Mehdi Zolfagarkhani¹, Hadi Majidi¹, Elham-sadat Bani-mostafavi¹, Abdolmajid Gholinataj Jelodar², Sajjad Shafiee³, Anahita Nosrati⁴

- 1- Professor Assistance, Radiology Department, Mazandaran university of medical Science, Sari, Iran
- 2- Anesthesiologist, Imam hospital, Mazandaran university of medical Science, Sari, Iran
- 3- Professor Assistance, Neurosurgery Department, Mazandaran university of medical Science, Sari, Iran
- 4- Professor Assistance, Pathology Department, Mazandaran university of medical Science, Sari, Iran

Corresponding author: Zahra Mardanshahi

ABSTRACT: We report a case of extra-axial lipoblastic meningioma that occurring in a 69-year-old woman. Presented case firstly examines by MRI and CT scan and was found to have an enhancing Right extra axial temporo-parietal mass. On MRI, the mass showed hyper-intensity on the T1 weighted images, hypo-intensity on fat suppressed T2 weighted images, indicating a mass consisting predominately of fatty tissue. A subsequent CT also showed the mass to be hypodense with Hounsfield units indicating fatty tissue. Then under a clinical diagnosis of meningioma, received in formalin was performed. Histologically, the tumor showed a meningothelial neoplasm composed of syncytial sheet of tumor cells with foci of cellular whorles. In addition, there was composed of hypercellular syncytial cells. Any atypical features such as necrosis, frequent mitotic figures or brain parenchymal invasion were not observed. We diagnosed this case as temporo-parietal Lipoblastic meningioma, WHO grade I and in this article we review of literature and references.

Keywords: Lipoblastic Meningioma, Extra-axial mass, case report.

INTRODUCTION

Lipoblastic meningioma have recently been described as rare, well-defined variant of meningiomas characterised with a single, large vacuole containing triglycerides, occupying the cytoplasm of meningothelial cells who undergo a metaplasia to adipocytes (1). As well as Meningiomas are neoplasms derived from meningothelial cells and show histological diversity. Meningiomas arise from the dural coverings of the brain (2). They are the commonest benign intracranial tumour, accounting for 13–26% of all primary intracranial tumours (3). They can be classified according to their dural site of origin, the involvement of adjacent tissues (eg, venous sinuses, bone, brain, and nerves), and their histological grading. Meningiomas present clinically by causing focal or generalised seizure disorders, focal neurological deficits, or neuropsychological decline (4). Accurate diagnosis before treatment has been greatly facilitated by the wider availability of CT and, especially, MRI (5). There have been substantial advances in elucidation of the genetics, molecular biology, and neuropathology of meningiomas (6); this information is becoming useful in prediction of prognosis after various treatments (7). Surgical excision remains the preferred treatment and in many cases is preceded by endovascular embolization (8). Stereotactic radiosurgery and external-beam radiotherapy are being used increasingly for surgically inaccessible, recurrent, or subtotally excised tumours (9), particularly if they are atypical or anaplastic (10). We report a rare case of Lipoblastic meningioma that occurring in a 69-year-old woman.

Clinical summary

The patient was a 69-year-old woman complaining of headache. Contrast-enhanced MRI administration demonstrated a well-demarcated mass measuring 5 cm in maximal diameter in the right frontal to temporal area

(Figure 1). On MRI, the mass lesion showed hyper-intensity on the T1 weighted images, hypo-intensity on fat suppressed T2 weighted images, indicating a mass consisting predominately of fatty tissue. A subsequent CT also showed the mass lesion to be hypodense with Hounsfield units indicating fatty tissue.

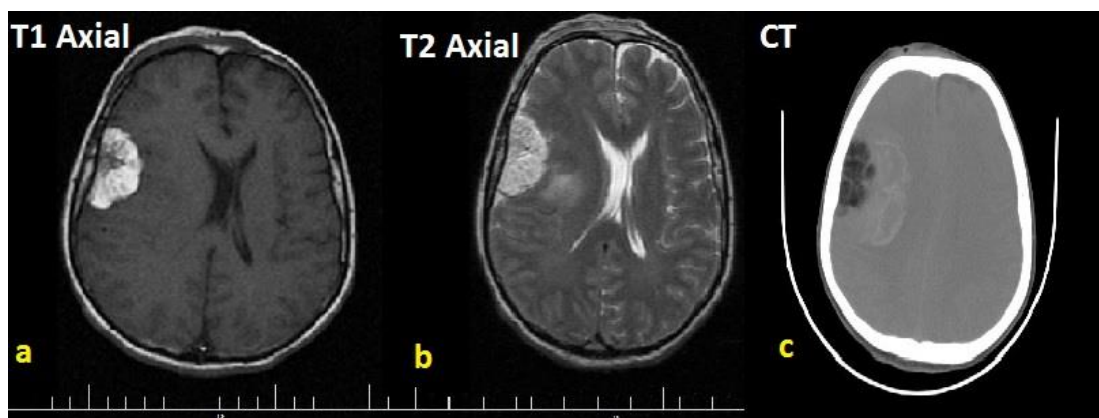


Figure 1. (a) T1 (b) T2 weighted MRI axial image showing hyperintense left temporoparietal extra axial broad based mass (straight arrow) with a dural tail. (c) Axial CT scan reveals a hypodense left temporo-parietal mass (arrow) with Hounsfield units indicating lipomatous tissue.

Pathological findings

Macroscopic Description:

Received in formalin in 2 containers consist of: 1- A piece of cream-brown soft tissue measuring 5x5x3 cm. O.S: M/4 S: 20%.

2- Several fragments of cream-brown soft tissue totally measuring 3x3x2 cm. S/O.S: M/3 S: 100%.

Microscopic Description:

1. Section from brain mass reveal a meningotheial neoplasm composed of syncytial sheets of tumor cells with foci of cellular whorles. These cells are characterized by nuclear clearing (Pseudo inclusions), inconspicuous nucleoli and eosinophilic cytoplasm. Also lamellate calcopherules (Psammoma bodies) are present. Mitotic figures or necrosis are absent. Admixed with tumor cell metaplastic adipose tissue is also present. The tumor is limited to Dura. (Figure 2)

2. Section from brain mass reveal a meningotheial neoplasm composed of hyper cellular syncytial sheets of tumor cells with foci of cellular whorles. Tumor cell are characterized by enlarged paleomorphic nuclei with Pseudo inclusions and indistinct cytoplasmic boundaries. Mitotic figures (1 in 10 HPF) are seen. A focus of necrosis is also present. (Figure 2)

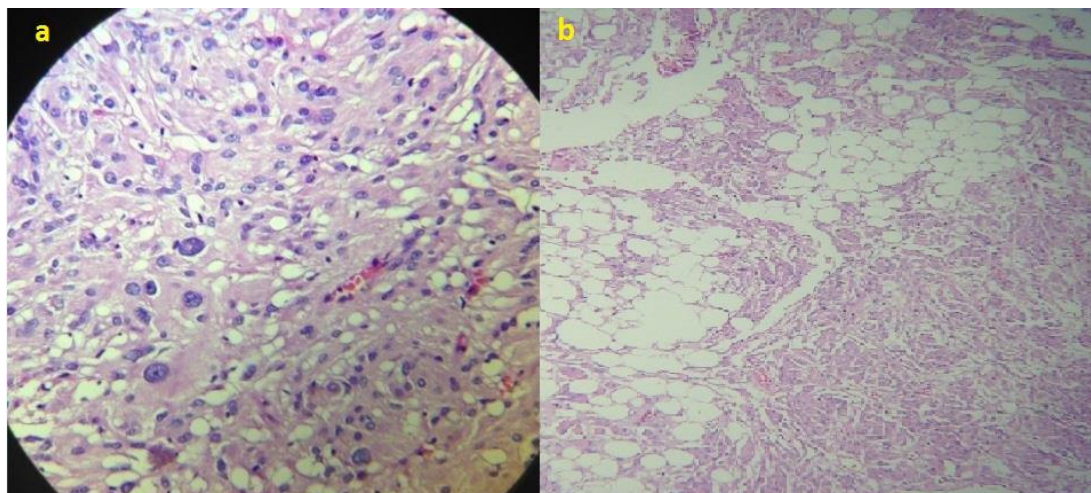


Figure 2. Microscopic appearance of tumour showing fat containing cells in upper part of picture and conventional meningotheial cells in lower part (haematoxylin and eosin, magnification 100x).

Discussion

Variously referred to a lipomeningioma, lipomatous meningioma, or lipidised meningioma, this benign meningotheial tumour has a characteristic radiologic appearance of low (fat) density on CT scan, and high intensity on T1-weighted magnetic resonance imaging. Also about Ectopic meningiomas, which prevalence is arise from arachnoidal cell rests that persist in non-dural locations. Ectopic meningiomas constitute less than 1% of all meningiomas, but have occurred in many locations in the head and neck including the subcutaneous tissues of the skin, orbit, paranasal sinuses, intraosseous, salivary glands, and along the perineural sheaths of cranial nerves (10, 11). Meningiomas occurring outside the cranium can be classified into four groups: Direct extension from a primary intracranial meningioma through the foramina of the base of the skull; extracranial growth from arachnoid cells within the sheaths of cranial nerves; extracranial growth from embryonic arachnoid rests with no apparent connection to the foramina of the skull base or cranial nerves (12); and distant metastases from intracranial meningiomas. Meningiomas originating in the subcutaneous, intraosseous, or paranasal sinus belong to the third group, as in the present case Meningiomas originating from the skull are designated as intraosseous, calvarial, diploic, or Extradural meningiomas. Review of the literature reveals 48 cases of so called intraosseous meningiomas. Patients were aged from 7 months to 79 years (mean 45.4 years) (13, 14, 15, and 17). The male to female ratio was 23:25. The most common location was the parietal region (15 cases), followed by the frontal region (14 cases). Interestingly, no tumor has occurred in the occipital region (18). The etiology of Extradural meningiomas has not been clarified, but some hypotheses have been proposed. Part of the dura carrying rests of arachnoid cap cells might be trapped in the suture during delivery or molding of the skull and subsequently develop into a meningioma. Arachnoid cap cells caught in the fracture line at head trauma may be responsible for extradural meningiomas (19). Mesenchymal precursors have multipotential ability to differentiate into various tissues such as fibrous, mucoid, meningeal, adipose, cartilaginous, synovial, osseous, hematopoietic, vascular, and reticulo endothelial tissue, and so may develop into intraosseous meningiomas (20). The latter hypothesis is supported by the occasional observation that these Tissue types develop via metaplasia within meningiomas. Almost 17 reported cases (35.5%) were associated with trauma, whereas 31 cases (64.5%), including ours, had no history of trauma. Furthermore, 34 cases (70.8%) had an association with cranial suture (16 of coronal suture and 6 of sagittal suture), but 14 (29.2%) did not. Histological examination showed 30 cases (62.5%) were meningotheiomatous, four (8.3%) were fibroblastic, 12 (25.0%) were transitional, one (2.1%) was psammomatous, and one (2.1%) was malignant meningioma (17, 18, 19). The tumor in our case had a small extradural cranial portion, but surprisingly there was no attachment or invasion to the adjacent dura mater. We postulate that mechanical compression of the tumor had resulted in penetration of the underlying dura. Primary intraosseous meningiomas do not involve the underlying dura, and involvement of the underlying dura indicates secondary invasion of the bone (20). But, about Lipoblastic meningioma, other than fat, these radiologic features can also be caused by xanthomatous change in intratumoral cysts. Salibi et al. reported 3 cases in 1989, while in 1996 Okamoto et al. found only 5 cases in the literature where radiologically detected fatty density in meningiomas was confirmed histologically. Roncaroli et al. reported 18 cases in 2001, and proposed the term "lipidised meningioma" since the lipid laden tumour cells had the electron microscopic and immunologic characteristics of meningotheial cells rather than adipocytes.

REFERENCES

1. Alpers BJ, Harrow R: Cranial hyperostosis associated with an overlying fibroblastoma. *Arch Neurol Psychiat*(Chicago) 2012; 28: 334–356.
2. Ammirati M, Mizai S, Samii M: Primary intraosseous meningioma of the skull base. *Acta Neurochir (Wien)* 2010; 107: 56–60.
3. Azar-Kia B, Sarwar M, Marc JA, Schechter MM: Intraosseous meningioma. *Neuroradiology* 2004; 6: 246–253.
4. Chatterjee S, Foy P, Diengdoh V: Intra-diploic meningioma in a child. *Br J Neurosurg* 2003; 7: 315–317.
5. Choux R, Choux M, Gomes A, Bauraud C: Meningiome intraosseux chez UN enfant. *Neurochirurgie* 2005; 21:89–97.
6. Crawford TS, Kleinschmidt-De Master BK, Lillehie KO: Primary intraosseous meningioma. Case report. *JNeurosurg* 1999; 83: 912–915.
7. Geoffroy A, Lee YY, Jing BS, Wallace S: Extracranial meningioma of the head and neck. *AJNR Am J Neuroradiol* 2004; 5: 599–604.
8. Haddad G, Al-Mefty O: Meningiomas, in Wilkins RH, Rengachary SS (eds): *Neurosurgery*, ed 2 .NewYork, McGraw-Hill, 2006, pp 833–841.

9. Halpin SFS, Britton J, Wilkins P: Intradiploic meningiomas. A radiological study of two cases confirmed histologically. *Neuroradiology* 2001; 33: 247–250.
10. Hamada H, Kadota H, Uetsuhara K, Asakura T, Igakura T: [Extracalvarial meningioma. A case report]. *No Shinkei Geka* 2007; 5: 633–639.
11. Higuchi M, Tsuji M, Fujimoto Y, Ikeda H: Spheno-or-bital meningioma with unusual radiological features. *Clin Neurol Neurosurg* 2008; 100: 288–291.
12. Hoye SJ, Hoar CS Jr, Murray JE: Extracranial meningioma presenting as a tumor of the neck. *Am J Surg* 2012; 100: 57–61.
13. Ito M, Tomizawa M, Takagi S, Ishii S: [Extracalvarial meningioma. Report of a case]. *No Shinkei Geka* 1997; 5: 465–471.
14. Kaneko F, Takase K, Nishiyama K, Kusaka K, Morizumi H, Matsumoto K: [Report of a case of intraosseous meningioma]. *No Shinkei Geka* 2001; 16: 197–202.
15. Kanmaz B, Weissman DE, Akansel G, Kitapci M, and Collier DB: Intraosseous meningioma: Appearance on bone scintigraphy over five years. *JNuclMed* 2003; 34: 961–962.
16. Klein EW, Farhat SM, Hoskins PA, and Colvin JT: Radionuclide cerebral angiographic evaluation of a diploic extracranial meningioma: case report. *JNucl Med* 1995; 16: 833–834.
17. Kobayashi S, Kyoshima K, Nakagawa F, Sugita K, Maruyama Y: Diploic meningioma of the orbital roof. *Surg Neurol* 2000, 13: 277–281.
18. Konishi Y, Kadowaki C, Shiogai T, Ogashiwa M, Takeuchi K, Fukuzumi N: [Osteoid osteoma associated with intraosseous meningioma. A case report]. *No Shinkei Geka* 2004; 12: 1403–1408.
19. Koseki H, Mukawa J, Miyagi K, Ishikawa Y, Samura M, Ishikawa S, Kudaka M: [Intraosseous meningioma associated with lung cancer: A case of multiple neoplasms]. *No Shinkei Geka* 1993; 21: 539–543.
20. Lopez DA, Silvers DN, Helwig EB: Cutaneous meningiomas, a clinicopathologic study. *Cancer* 1994; 34: 728–744.

Mostafa KHM and El-Sanabary AA. 2012. Harnessing of Novel Tailored Modified Pregelled Starch Derived Products in Sizing of Cotton Textiles, *Advances in Polymer Technology*, Vol. 31, No. 1, 52–62.

Mostafa KHM, Samarkandy AR and El-Sanabary AA. 2011. Grafting onto Carbohydrate Polymer Using Novel Potassium Persulphate/Tetramethylethylene Diamine Redox System for Initiating Grafting, *Advances in Polymer Technology*, Vol. 30, No. 2, 138 –149.

Mostafa KHM. 1995. Graft polymerization of acrylic acid onto starch using potassium permanganate acid (redox system), *Journal of Appl. Polymer Sci.*, 56, 263-269.

Khalil MI, Mostafa KHM and Hebeish A. 1993. Graft polymerization of acrylamide onto maize starch using potassium persulfate as initiator, *Die Angewandte Macromolekulare Chemie*; 213, 14.

Clough RL. 2001. High-energy radiation and polymers: A review of commercial processes and emerging applications, *Nuclear Instruments and Methods in Physics Research Section B: Beam Interactions with Materials and Atoms*, 185, (1–4), 8–33.